

See discussions, stats, and author profiles for this publication at: <https://www.researchgate.net/publication/254274110>

An Epizootic of Cutaneous Fibropapillomas in Green Turtles *Chelonia mydas* of the Caribbean: Part of a Panzootic?

Article in *Journal of Aquatic Animal Health* · March 1994

DOI: 10.1577/1548-8667(1994)006<0070:AEOCF>2.3.CO;2

CITATIONS

54

READS

115

11 authors, including:



Ernest H. Williams, Jr

University of Puerto Rico at Arecibo

158 PUBLICATIONS 3,116 CITATIONS

[SEE PROFILE](#)



Lucy Bunkley Williams

University of Puerto Rico at Mayagüez

111 PUBLICATIONS 2,220 CITATIONS

[SEE PROFILE](#)



Esther Peters

George Mason University

44 PUBLICATIONS 2,689 CITATIONS

[SEE PROFILE](#)



Antonio A. Mignucci-Giannoni

Interamerican University of Puerto Rico, Bayamon, Puerto Rico

117 PUBLICATIONS 1,575 CITATIONS

[SEE PROFILE](#)

Some of the authors of this publication are also working on these related projects:



Belize Lionfish Project [View project](#)



Life history of Caribbean marine mammals [View project](#)

An Epizootic of Cutaneous Fibropapillomas in Green Turtles *Chelonia mydas* of the Caribbean: Part of a Panzootic?

ERNEST H. WILLIAMS, JR. AND LUCY BUNKLEY-WILLIAMS

*Caribbean Aquatic Animal Health Project, Department of Marine Sciences
University of Puerto Rico, Post Office Box 908, Lajas, Puerto Rico 00667-0908, USA*

ESTHER C. PETERS¹

*Registry of Tumors in Lower Animals, National Museum of Natural History
NHB-163, Washington, D.C. 20560, USA*

BENITO PINTO-RODRÍGUEZ AND ROBERT MATOS-MORALES

*Department of Natural Resources, Commonwealth of Puerto Rico
Post Office Box 5887, Puerta de Tierra, Puerto Rico 00906-5887, USA*

ANTONIO A. MIGNUCCI-GIANNONI

*Caribbean Stranding Network, Department of Marine Sciences
University of Puerto Rico, Post Office Box 908, Lajas, Puerto Rico 00667-0908, USA*

KATHLEEN V. HALL²

*Sea Turtle Stranding and Salvage Network of the Southeastern United States and
Fisheries Research Laboratory, Commonwealth of Puerto Rico
Post Office Box 3665, Mayaguez, Puerto Rico 00709, USA*

JOSÉ VICENTE RUEDA-ALMONACID

*Instituto Nacional de los Recursos Naturales Renovables y del Ambiente (INDERENA)
Apartado Aéreo 13458, Bogotá, República de Colombia*

JEFFREY SYBESMA

*Caribbean Marine Biological Institute, Netherlands Antilles National Parks Foundation
Post Office Box 2090, Piscadera Baai, Curaçao, Netherlands Antilles*

IDELISA BONNELLY DE CALVENTI

Guarocuya 90, El Millón, Santo Domingo, República Dominicana

RALF H. BOULON

*Division of Fish and Wildlife, Department of Planning and Natural Resources
Government of the Virgin Islands
101 Estate Nazareth, St. Thomas, U.S. Virgin Islands 00802, USA*

Abstract. — An epizootic of fibropapillomas in green turtles *Chelonia mydas* (Reptilia: Testudines: Cheloniidae) has occurred throughout the Caribbean since the mid-1980s. Similar epizootics in Hawaii and Florida began 5 years earlier. All may be part of a panzootic. The 125 Caribbean cases greatly expand the known range of these epizootics. All the tumors we examined had spirorchiid (Digenea) eggs. Few turtles we examined with tumors were emaciated. Additional tumors quickly erupted in some captive turtles, whereas tumors of others remained unchanged for 1 year. The turtle leech *Ozobranchus branchiatus* (Hirudinea: Ozobranchidae) was associated with only three green turtles with fibropapillomas.

¹ Present address: Tetra Tech, Inc., 10306 Eaton Place, Suite 340, Fairfax, Virginia 22030, USA.

² Present address: Caribbean Sea Turtle Stranding and Salvage Network, 33 Las Marinas Street, Isabela, Puerto Rico 00662, USA.

Smith and Coates (1938, 1939) described "fibro-epithelial growths" from the skin of green turtles *Chelonia mydas* (Reptilia: Testudines: Cheloniidae) from the Florida Keys. Since 1982, cases of fibropapillomas in this species seem to be more

TABLE 1.—Recent reports of fibropapillomas in green turtles from outside of the Caribbean. NR = not reported.

Locality	% with tumors	Number examined	Date	Reference
Florida				
Florida Keys	52.0	134	1983–1989	Jacobson et al. (1991b)
Indian River	55.0	NR	1982–1985	Ehrhart (1991)
	57.0	53	1985–1986	Jacobson et al. (1989)
	33–61	144	1986–1990	Ehrhart (1991)
Hawaiian Islands				
Entire area, strandings ^a	31.0	27	1983	Balazs (1991)
	26.0	33	1984	Balazs (1991)
	40.0	52	1985	Balazs (1991)
	31.0	105	1986	Balazs (1991)
	47.0	110	1987	Balazs (1991)
	46.0	75	1988	Balazs (1991)
	52.0	110	1989	Balazs (1991)
	53.0	154	1990	Balazs (1991)
Palau	10.0	143	1989	Balazs (1991)
	25.0	182	1990	Balazs (1991)
Maui	77–85	NR	1989–1990	Balazs (1991)
Kaneohe Bay	49–92	121	1989–1990	Balazs (1991)

^a Strandings data compiled for all of the Hawaiian Islands by the Sea Turtle Stranding and Salvage Network of Hawaii.

common and spreading geographically, sometimes as epizootics (Balazs 1991; Jacobson 1991; Table 1). Since the mid-1980s, we have seen an epizootic of fibropapillomas in green turtles of the Caribbean. The recent drastic increases in this unexplained condition may represent a panzootic.

Fibropapillomas on the green turtle are lobulated tumors on the skin, scales, scutes, eyes and surrounding tissues, oral cavities, and viscera. This descriptive term is based on the morphological appearance of the papillary pattern in the early lesion and the predominance of fibrous connective tissues (Balazs and Pooley 1991). These tumors begin as small growths and may increase to 30 cm or more in diameter. They may grossly disfigure much of the soft external tissues and may interfere with vision, breathing, feeding, and swimming (Balazs and Pooley 1991). Internal tumors also occur in some turtles with external fibropapillomas, but the relationship between these internal lesions and the cutaneous fibropapillomas has not been established (Balazs and Pooley 1991). The cause of this problem is not known, but trematode eggs are usually present, and a herpesvirus has recently been found in these tissues (Jacobson et al. 1991a). This condition may be a substantial threat to the survival of this already threatened turtle (Balazs and Pooley 1991).

We describe a recent epizootic of fibropapillomas in Caribbean green turtles, compare this with other recent fibropapilloma epizootics in this animal, and suggest that a panzootic is occurring. We also report general biological information about fibropapillomas of this species.

Methods

All fibropapilloma cases marked in Table 2 as confirmed histologically, except the two cases from Colombia and the 1980 case from the Cayman Islands, were confirmed by one or more of us, or by the Registry of Tumors in Lower Animals, Smithsonian Institution. Those marked in Table 2 as not examined histologically were only grossly examined externally by us or our colleagues. We used a variety of necropsy and histology techniques on these turtles. A representative case is described below.

On 15 April 1990, a debilitated green turtle that had external tumors and was 72 cm long (all lengths are curved-carapace standard lengths) became snagged in a fishing line south of Ponce, Puerto Rico. The animal was captured and transferred by the Department of Natural Resources of the Commonwealth of Puerto Rico to the Caribbean Aquatic Animal Health Project (CAAHP) and Caribbean Stranding Network (CSN) on 18 April for treatment and rehabilitation (case numbers: CAAHP 900418-A, Sea Turtle Stranding and Salvage Network [STSSN] 4-19-1990, CSN NEP-CH-007). It was held in seawater in an aboveground circular plastic pool 3.5 m wide and 0.9 m deep until it died the same day. Soon after death, a 1.6-cm tumor from the right eye was excised with a scalpel, and samples of tumor tissue were cut from the body anterior of the right front flipper ($N = 2$, 3×2 cm), and anterior of the right rear flipper ($N = 4$, 3×1.8 cm to 4×3 cm). The samples were fixed in 10% formalin and sent to the Reg-

TABLE 2.—Records of green turtles from the Caribbean with fibropapillomas. Where no data are given, information was either not reported or not applicable.

Locality	Date	Host		Tumor ^b				Examiner ^d	
		Num-ber exam-ined	Size ^a (cm)	Number	Size ^c	Site	Status	Name	RTLA case number
Puerto Rico									
East coast	1985	1		A	L-S			RM	
Cabo Rojo	1986	1		A	L-S	BNFT		RM	
Dorado	15 May 1987	1	60 × 53	A	2-10	NFTI	CU	RM	
Humacao	26 Jun 1987	1	65 × 59	A	2-3	HFTBN	CU	BP, RM, MC	3855
Culebra Island	15 Jun 1988	1	72.7 × 54.7	1	1.5	ER		RB	
Ceiba	9 May 1989	1	64.6 × 60	20	L-S	BNE		BP	
Ponce	19 Apr 1990	1	72 × 68.9	A	L-S	BNEI	CX	CA, KH, BP	5172
Carolina	4 May 1990	1	69 × 57	A	L-S	BEHI	D	BP, AM, PR	
		1	70 × 58	A	L-S	BEH	D	BP, AM, PR	
San Juan	22 Jan 1991	1	56 × 49	A	L-S	BNE	D	BP, RM	
Ceiba	19 Mar 1991	1	53 × 48	A	1-6	NFTEBGI	C	BP	5395
	19 Mar 1991	1	57.4 × 52.5	A	L-S	EGLVZI	C	BP	5697
Carolina	5 Aug 1991	1	43 × 35	11	L-S	BFNEP	C	BP, CA	
Congrejos Bay	22 Nov 1991	1	61.6 × 54.4	A	L-S	BEFGHNI	CX	AM, BP	5696
Pájaros Beach	24 Dec 1991	1	66 × 61	5	M-S	FP	C	BP	5699
Carolina	4 Feb 1992	1	47.5 × 43.5	13	L-S	GKOVI	CX	BP	5700
	6 May 1992	1	56.5 × 51.0	A	L-S	BNEF	C	BP	
Cayman Islands									
Turtle Farm	1980	1				ENBF	CU	J89	
	21 Sep 1982	1		5	S-M	HE	C	JF	3099
Grand Cayman	1986	1	50	A	L	BNFR		PB	
Netherlands Antilles									
Curaçao	13 Mar 1989	1	60 × 50	A	M-S	BNET	CX	JS	
	28 Feb 1990	3		A	L-S	B		JS	
Unspecified		1						JPC	
U.S. Virgin Islands									
St. Thomas	3 Oct 1985	1	68.8 × 53.5	3	1.7	FR		RB	
		1	66.2 × 51.6	Few	<1	NER		RB	
		1	53.4 × 43.8	Few	<1	FNR		RB	
Colombia									
Guajira Peninsula	Spring 1988	6	50-82	Few-A	L-S	BNFEH	C	RA	
	Aug 1988	19	50-82	1-40	L-S	BHFEHT	C	RA	
Dominican Republic									
Manzanillo Bay	Oct 1969	1	76	N	L-S	NFEB	C	IB	
Santo Domingo	15 Oct 1990	1	64 × 72	80	1-5	FNB	C	AM	5394
Bahamas									
Grand Bahama	mid-1980s	5	50-60	A	L-S	BFH		BR	
Unspecified		1						JPC	
Belize	May 1990	3		A	2-3	NB		KE	
Venezuela	Oct 1990	1	80.5	A		ENF		GPC	
Antigua and Barbuda									
Antigua	1987	6		A	L-S	BHF		KH, B89	
Barbados	1986-1990	50		A	L-S	BHN		G&HPC	
Mexico	1977	2						FW	
Panama		1						JPC	
Trinidad and Tobago									
Trinidad		1						J91	

^a Size given as standard length only (curved carapace measurement) or standard length × maximum width.

^b Abbreviations: A = abundant, B = body (nonshell surfaces other than neck, flippers, and tail), C = confirmed histologically, D = too decomposed to examine histologically, E = eye, F = flippers, G = lung, H = head, I = internal lesions in viscera, K = kidney, L = large, M = medium, N = neck, O = ovary, P = carapace plate, R = no necropsy because turtle was released without tagging or with tagging (tag numbers: AAR719-720 in Culebra; AAG702-703, 704-705, 706-707 in St. Thomas), S = small, T = tail, U = leeches associated with tumors, V = liver, X = emaciated, and Z = heart.

^c Description or measurement (cm).

^d RTLA = Registry of Tumors in Lower Animals. Abbreviations of the examiners: AM = A. Mignucci, B89 = Bjørndal (1989), BP = B. Pinto, BR = B. Rose (Underwater Explorers Society, personal communication), CA = Caribbean Aquatic Animal Health (E. Williams, L. Bunkley-Williams, and A. Mignucci), FW = F. Wood (personal communication), GPC = H. J. Guada (National Parks of Venezuela, personal communication), G&HPC = N. Gamache and J. Horrocks (Bellaires Research Institute, personal communication), IB = I. Bonnelly de Calventi, J89 = Jacobson et al. (1989), JPC = Jacobson (personal communication), J91 =

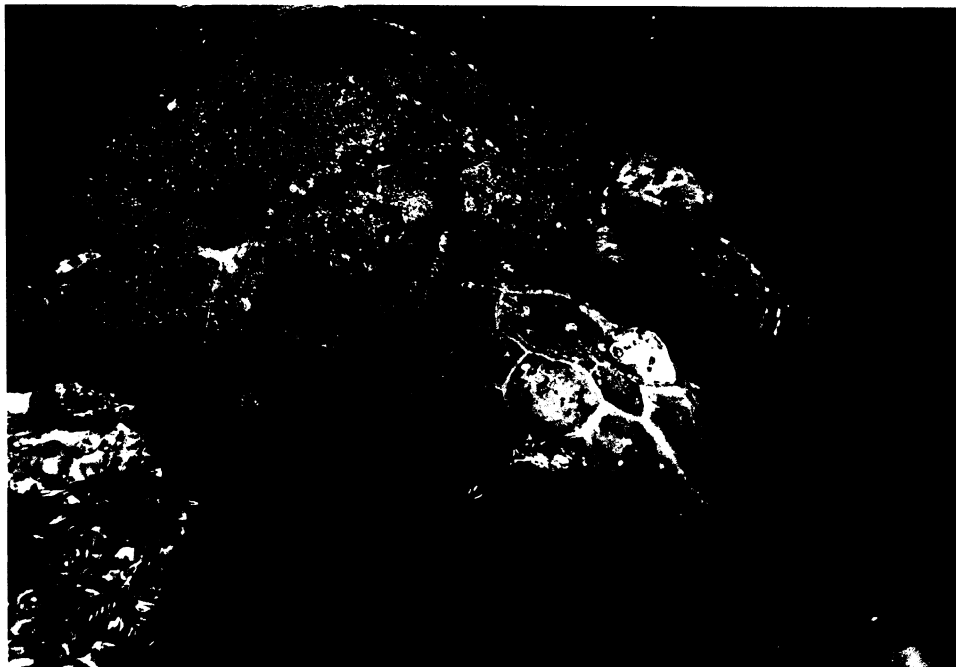


FIGURE 1.—Fibropapillomas on flippers, neck, body, and eye of a green turtle (72 cm curved carapace length) from Puerto Rico. Photograph by L. Bunkley-Williams.

istry of Tumors in Lower Animals (RTLA 5172), where paraffin sections were stained in hematoxylin and eosin.

Portions of the alimentary canal, lungs, heart, and blood vessels were examined for metazoan parasites with a dissection microscope. Spirorchiid digeneans were removed with a pipette from the blood vessels and heart, and other digeneans were recovered from the alimentary canal with forceps. All digeneans were deposited in the Helminthological Collection of the National Museum of Natural History and cataloged under numbers of the U.S. National Museum (USNM) (Dyer et al. 1991). Blood smears and wet mounts were examined for spirorchiid digenea and ova by C. E. Cutress (Department of Marine Sciences, University of Puerto Rico).

The visceral organs of the green turtle specimen from Curaçao were examined histologically. We

only histologically examined organs that appeared to have tumors in the other cases. Some turtle information was collected by tagging programs in St. Thomas and St. Croix. Green turtles with tumors held in the National Aquarium of the Dominican Republic were examined and measured, and their tumors were measured and biopsied in October 1990 and October 1991.

Leeches were relaxed by refrigeration and preserved in 10% formalin. All specimens were deposited in USNM, Division of Worms.

Results

We report 125 cases of tumors in green turtles from 14 Caribbean countries (Table 2; Figure 1). We histologically confirmed fibropapillomas in 10 green turtles from Puerto Rico, 2 from the Dominican Republic, 25 from Colombia, and 1 each from Curaçao and the Cayman Islands. The tu-

←
Jacobson (1991), JF = J. Frazier (Smithsonian Institution, personal communication), JS = J. Sybesma, KE = K. Eckert (personal communication), KH = K. Hall, MC = M. Córbet (Natural Resources Laboratory of the Cayman Islands, personal communication), PB = P. Busch (Natural Resources Laboratory of the Cayman Islands, personal communication), PR = P. Rivera (Department of Natural Resources, Commonwealth of Puerto Rico, personal communication), RB = R. Boulon, RM = R. Matos, and RA = J. Rueda.



FIGURE 2.—Photomicrograph of fibropapilloma from a green turtle (64 cm curved carapace length) from the Dominican Republic. Photograph by E. C. Peters.

mors on 86 other green turtles were examined grossly and appear to represent the same condition, but were not confirmed histologically (Table 2). One case typical of our examinations is described below.

Histologically, the five lesions sampled in the 72-cm-long green turtle from Puerto Rico exhibited dense, well-vascularized, fibrous masses (Figure 2). The collagenized fibers were generally arranged in a herringbone pattern. Capillaries were distributed throughout the mass and were usually ringed by dendritic melanocytes. Ova of a spirorchiid digenean appeared in some sections of capillaries. These were probably from adults of *Lea-*

edius learedi (USNM 801202), which occurred in the blood vessels and heart of this specimen of turtle, but several other spirorchiids are known from this turtle species, and their ova are difficult to identify in histological sections. No ova were found in blood samples. The fibrocytes were infiltrating and disrupting underlying muscle fibers. In a few areas, the fibers exhibited decreased density, appearing almost myxoid. Mitotic figures were rare here, as well as in the epidermis. In some areas of the epidermis, bacterial colonies were visible in the cornified layer. In other areas, the tumors had well-differentiated and keratinized epidermis. Noninvasive epidermal pegs interdigitated

with connective tissue papillae. The epidermis of the tumors had slightly more basal cells and prickle cells than the normal epidermis.

The green turtle from Curaçao had a necrotic liver and the lungs were edematous and contained numerous unidentified spirorchiid (*Digenea*) ova. Spirorchiid ova occurred in all of the fibropapillomas examined histologically.

Only four green turtles with tumors were emaciated: three from Puerto Rico and one from Curaçao (Table 2). In the Puerto Rican specimen from Ponce, we could determine no physical cause of the emaciation other than the tumors; the gastrointestinal tract was filled with food, and the number of parasites was not considered sufficiently damaging to cause the observed emaciation (Dyer et al. 1991).

Internal growths occurred in 7 of the 17 green turtles with cutaneous fibropapillomas examined from Puerto Rico (Table 2). The growths from two of these turtles were too decomposed to examine, two turtles showed no fibrous lesions, but three had fibromatosis. The lesions in the lungs and kidneys of these green turtles were fibrous and infiltrative, elicited a weak granulomatous response, but were not overly reactive (J. C. Harshbarger, RTLA, personal communication).

Tumors of the 64-cm-long green turtle held in the Dominican Republic remained unchanged over a period of 1 year (October 1990–October 1991). Additional tumors erupted on the plastron of a 43-cm-long green turtle in a period of 2 months. We held the turtle in Puerto Rico for 4 months (August–December 1991).

Leeches were found on only three of the Caribbean green turtles with fibropapillomas (two of the cases we examined; Table 2).

Discussion

In the past 15 years, epizootics of fibropapillomas occurred in wild green turtles in east-central Florida and Hawaii, and in cultured green turtles in the Cayman Islands (Jacobson 1981; Jacobson et al. 1989). Three new cases also occurred in San Diego, California (D. McDonald and P. Dutton, Sea World Research Institute, personal communication). There is concern that this condition is increasing in prevalence in Florida, California, and Hawaii, and may be spreading geographically (Balazs and Pooley 1991). The Caribbean cases we report (Table 2) may be a part of this widespread pattern. Prevalence in Barbados has drastically increased in the last 4–5 years, and 70–80% of all commercially captured green turtles have

been affected (Balazs and Pooley 1991). The recent outbreaks in the Caribbean may be more common than our records (Table 2) indicate. Fibropapillomas are very common on green turtles around Puerto Rico (B. Pinto and R. Matos, unpublished data), Belize (K. L. Eckert, Marine Turtle Newsletter, personal communication), Curaçao (J. Sybesma, unpublished data), and Venezuela (H. J. Guada, National Parks of Venezuela, personal communication). Jacobson (1991) reported fibropapillomas in green turtles from the Bahamas, Belize, the Netherlands Antilles, Panama, and Trinidad. These outbreaks could be the beginning of a serious panzootic in a species that is already threatened or endangered over much of its range.

Epizootics of this tumor in green turtles began in the last decade (Balazs and Pooley 1991; Table 1). Ehrhart (1991) found no fibropapillomas among the hundreds of green turtles he had captured in east-central Florida prior to 1982. More than half of the green turtles captured in late 1985 to early 1986 were affected (Table 1). No cases of this tumor were reported on the south coast of Molokai, Hawaiian Islands, prior to October 1985 (Balazs 1991). Fibropapillomas have only recently (in 1990) appeared on green turtles in California (McDonald and Dutton, personal communication). We have stranding records for green turtles in Puerto Rico since 1984, but tumor cases were not reported until 1987 (the 1985 and 1986 records were not STSSN cases; Table 2). In St. Thomas, more than 400 green turtles have been examined since 1980, but tumors have only been noted since 1985 (R. Boulon, unpublished data; Table 2). Cases in Barbados dramatically increased since around 1986 (Balazs and Pooley 1991). The epizootics and West Indian cases are all relatively recent, except for the 1969 case in the Dominican Republic (Table 2).

The Caribbean cases (Table 2) closely conform with the description of previous cases reported. The Caribbean epizootic seems to have begun abruptly, similarly to the one in Florida, whereas the epizootic in Hawaii seems to have begun gradually (Table 1). The abruptness of the Caribbean epizootic does not seem to be simply inadequate recording. The Caribbean Stranding Network records in Puerto Rico show an abrupt beginning, and we were unable to find any previous Caribbean cases in wild green turtles other than the single 1969 case (Table 2). We cannot explain why the Caribbean epizootic began about 5 years after those in Florida and Hawaii. The Caribbean epizootic also differs from those limited to the small

area around Hawaii, or in a few locations in Florida, by including a much greater geographic area. If we are correct in extrapolating our results to the entire Caribbean region, then this epizootic represents an enormous increase in the areas where epizootics are occurring. Even though the epizootics affecting the three regions do show some differences, we feel that they are sufficiently similar and dispersed to represent a panzootic of this condition.

Fibropapillomas on green turtles are also known from Malaysia (Hendrickson 1958), Japan (E. R. Jacobson, University of Florida, personal communication), Australia (Jacobson 1991), and the French Frigate Shoals (part of the Hawaiian Islands) (Harshbarger 1991). The distribution of this condition may be circumtropical and subtropical.

In addition to green turtles, fibropapillomas have been histologically confirmed on loggerheads *Caretta caretta* from Indian River, Florida (Harshbarger 1991). Additional loggerheads with fibropapillomas have been found in two additional localities in Florida (Harshbarger, personal communication). Harshbarger (1991) also reported nasal warts from a hawksbill *Eretmochelys imbricata* in an aquarium in Germany, but he was not certain if this lesion was a fibropapilloma. Related tumors may also occur in other species of sea turtles, such as olive ridley *Lepidochelys olivacea* and black turtle *Chelonia agassizi* in the eastern Pacific, but these have not been examined histologically.

The cause of these fibropapillomas has not been established. Jacobson et al. (1989) suggested that an infectious agent, most likely a virus, was the etiological agent. The increased numbers of tumors could possibly be related to the increasing seawater temperatures in the 1980s (Williams and Bunkley-Williams 1990). Some viruses are activated by increased temperatures (Lucke et al. 1953; White and Fenner 1986), and some papillomas are temperature dependent (Sundberg 1991). The water temperatures in the Cayman Turtle Farm facilities at Grand Cayman Island, and in Indian River, Florida, where epizootics occurred, were probably higher than in the surrounding open ocean areas. Disease and mortalities of coral reef organisms were linked to increased seawater temperatures in 1980, 1983, 1987, and 1990 (Williams and Bunkley-Williams 1990), but the simultaneous occurrence of many of the tumors in Caribbean green turtles may only be a coincidence.

The only irritants that have been present in ev-

ery fibropapilloma case are spirorchiid ova, but these eggs are also present in tissues of green turtles without fibropapillomas (Harshbarger, personal communication). Trematode ova are common in both external and internal lesions, but their role in initiating the tumor is unclear. Fibropapillomas could be reactive rather than neoplastic (Harshbarger, personal communication). Spirorchiid ova occurred in all of the fibropapillomas that we examined histologically. The viral cause has only been suggested because similar conditions in other animals are caused by viruses (Smith and Coates 1938; Jacobson et al. 1989) and a herpesvirus has recently been found in tissues of green turtles (Jacobson et al. 1991a). Transmission between turtles seemed to occur during the Cayman Island epizootic (Jacobson 1981). Direct transmission experiments have thus far been unsuccessful (Jacobson, personal communication). The epizootic spread of this condition in other areas has appeared to follow patterns that might be expected in an infectious disease, but transmission has not been demonstrated. Our information concerning fibropapillomas in the Caribbean is too incomplete to suggest any patterns.

Available information is insufficient to entirely evaluate the damage that fibropapillomas may do to the green turtle, but circumstantially this condition seems to be highly detrimental and probably life threatening (Balazs and Pooley 1991). Fibropapillomas can cause severe emaciation in green turtles, but the exact percentage of turtles in which this occurred has not been reported (Balazs and Pooley 1991). Many of the tumors we have observed in Puerto Rico might have limited the sight and feeding of the animal, as has been suggested for affected green turtles in Florida (Jacobson et al. 1989), thus causing emaciation. The snagging in a fishing line may have been facilitated by the projecting tumors, but sea turtles without tumors are frequently snagged.

Turtles with fibropapillomas are anemic and occasionally have internal as well as external tumors, but the percentages with internal tumors are not known (Jacobson, personal communication). Schlumberger and Lucke (1948) described the occurrence of fibromas in the lungs of one of three green turtles captured off Cape Sable, Florida. Although these tumors may have resulted from metastasis of the cutaneous papillomas also found on this turtle, these two researchers thought that an origin in situ was more probable. More recently, Norton et al. (1990) reported finding multiple large white nodules in both kidneys of a 7-kg juvenile

green turtle from the Florida Keys after unsuccessful surgery to remove cutaneous fibropapillomas. The kidney lesions were diagnosed as myxofibromas, although the authors noted, "Histologically, the renal myxofibroma and dermal component of the fibropapillomas were indistinguishable." Fibromas were also found in the lungs and esophagus, stomach wall, and intestine of this same individual (Harshbarger 1991). Harshbarger (1991) also found fibromas (or fibrosarcomas) internally in three other cases submitted to the RTLA from Hawaii (RTLA 1774, 3615, 4233). Internal masses occurred in seven of the turtles from Puerto Rico examined in the present study (Table 2). This material was examined histologically in only five of these turtles and three (RTLA 5696, 5697, 5700) had fibromatosis.

Fibropapillomas on green turtles may not always be fatal. Jacobson et al. (1989) found that some tumors decreased in size during several months of observations, Ehrhart (1991) found that these tumors regress in older turtles and can be lost in both captive and tagged-and-recaptured turtles, and J. Homcy (Marine Life Center, personal communication) noted that some tumors shrank and others grew and changed colors in captive turtles. We have seen tumors quickly erupt or remain totally unchanged for a year in captive turtles. There seems to be a great deal of variation in how fibropapillomas develop.

These tumors have been thought to increase the green turtle's susceptibility to parasitism by the marine leech *Ozobranchus branchiatus* (Balazs and Pooley 1991) or to attract this leech (Ehrhart 1991). Williams et al. (1994) found this leech in Puerto Rico (USNM 132423). Small specimens of this leech were associated with fibropapillomas in only two of the turtles with tumors we examined (Table 2) (Matos et al. 1987). This leech has been seen for many years on green turtles in the Cayman Islands (F. Wood, Cayman Islands Turtle Farm, personal communication). Jacobson (1981) reported *Ozobranchus* sp. from green turtle tumors in the Cayman Islands. We found *Ozobranchus branchiatus* (USNM 132447) on green turtles in St. John that did not have external tumors. The close association of fibropapillomas and this leech, which has been reported by others, did not occur in most of our tumor samples.

An epizootic of fibropapillomas in the green turtle has been occurring since the mid-1980s in the Caribbean. This seems very similar to epizootics in Florida and Hawaii, and these may all be part of a panzootic. These tumors occasionally

occur on loggerheads, and possibly hawksbills and other sea turtles. Currently, however, we know very little about this widespread and important panzootic.

Acknowledgments

We thank Ramón L. Díaz and Antonio Rivera of the Ranger Corps (Department of Natural Resources, Commonwealth of Puerto Rico) for bringing an incapacitated turtle to our project; Kathy L. Price (RTLA) for preparing histological sections of tumors; Charles E. Cutress for examining blood and blood vessels; William G. Dyer (Southern Illinois University) for examining the Digenea; Ingrid van der Gaag (Faculty of Veterinary Medicine, University of Utrecht) for examining tumors from Curaçao; Karen Eckert (WIDECAST and Marine Turtle Newsletter) for preprints and articles from the newsletter; C. E. Cutress, K. Eckert, Richard K. Wallace (Alabama-Mississippi Sea Grant), Fern Woods (Cayman Islands Turtle Farm), Zandy Hillis (Virgin Islands National Park), Jennifer Homcy (Marine Life Center of Juno Beach, Florida), Nancy Lee, Benjamin Rose (Underwater Explorers Society, Freeport, Grand Bahama, Bahamas), and Philippe G. Busch (Natural Resources Laboratory, Grand Cayman, Cayman Islands) for observations of sea turtles with tumors; John C. Harshbarger (RTLA) and K. Eckert for reviewing the manuscript; Monica Vega (Acuario Nacional) for allowing the biopsy of the tumor in the Dominican Republic, and Oswaldo Vazquez (Centro de Investigaciones Biología Marina, Universidad Autónoma de Santo Domingo), Rubby A. Montoya, and Maluni Pagán for assisting with the biopsy; Freddie Rodríguez for helping transport and hold a live turtle; and Dallas Alston for the use of his holding tank for the 72-cm-long turtle. Cases in Puerto Rico were examined under authority of yearly permits issued by the Department of Natural Resources to the Caribbean Stranding Network.

References

- Balazs, G. H. 1991. Current status of fibropapillomas in the Hawaiian green turtle, *Chelonia mydas*. Pages 47-57 in Balazs and Pooley (1991).
- Balazs, G. H., and S. G. Pooley, editors. 1991. Research plan for marine turtle fibropapilloma. NOAA (National Oceanic and Atmospheric Administration) Technical Memorandum NMFS (National Marine Fisheries Service) SWFSC-156, Southwest Fisheries Science Center, Honolulu, Hawaii.
- Bjorndal, K. 1989. Rapporteur report of the green turtle

- status panel session. Pages 95–100 in L. H. Ogren and seven coeditors. Proceedings of the Second Western Atlantic Turtle Symposium. NOAA (National Oceanic and Atmospheric Administration) Technical Memorandum NMFS (National Marine Fisheries Service) SEFC-226, Southeast Fisheries Center, Panama City, Florida.
- Dyer, W. G., E. H. Williams, Jr., and L. Bunkley-Williams. 1991. Some digeneans of the green turtle, *Chelonia mydas*, from Puerto Rico. *Journal of the Helminthological Society of Washington* 58:176–180.
- Ehrhart, L. M. 1991. Fibropapillomas in green turtles of the Indian River Lagoon, Florida: distribution over time and area. Pages 59–61 in Balazs and Pooley (1991).
- Harshbarger, J. C. 1991. Sea turtle fibropapilloma cases in the Registry of Tumors in Lower Animals. Pages 63–70 in Balazs and Pooley (1991).
- Hendrickson, J. R. 1958. The green turtle (*Chelonia mydas*) in Malay and Sarawak. Proceedings of the Zoological Society of London 130:456–566.
- Jacobson, E. R. 1981. Virus associated neoplasms of reptiles. Pages 53–58 in C. J. Dawe, editor. Phyletic approaches to cancer. Japanese Science Society Press, Tokyo.
- Jacobson, E. R. 1991. An update on green turtle fibropapilloma. Pages 71–73 in Balazs and Pooley (1991).
- Jacobson, E. R., C. Buergelt, B. Williams, and R. K. Harris. 1991a. Herpesvirus in cutaneous fibropapillomas of the green turtle, *Chelonia mydas*. *Diseases of Aquatic Organisms* 12:1–6.
- Jacobson, E. R., and seven coauthors. 1989. Cutaneous fibropapillomas of green turtles (*Chelonia mydas*). *Journal of Comparative Pathology* 101:39–52.
- Jacobson, E. R., S. B. Simpson, Jr., and J. P. Sundberg. 1991b. Fibropapillomas in green turtles. Pages 99–100 in Balazs and Pooley (1991).
- Lucke, B., L. Berwick, and P. Nowell. 1953. The effect of temperature on the growth of virus-induced frog carcinoma. II. The temperature coefficient of growth in vitro. *Journal of Experimental Medicine* 97:505–509.
- Matos, R., H. Horta, M. Corbet, P. J. Rivera, and M. A. Nieves. 1987. Sea turtle hatchery project with specific reference to the leatherback turtle (*Dermochelys coriacea*) and hawksbill (*Eretmochelys imbricata*) sea turtles, Humacao, Puerto Rico. Department of Natural Resources, Forest Service, Bureau of Natural Reserves and Refuges, San Juan, Puerto Rico.
- Norton, T. M., E. R. Jacobson, and J. P. Sundberg. 1990. Cutaneous fibropapillomas and renal myxofibroma in a green turtle, *Chelonia mydas*. *Journal of Wildlife Diseases* 26:265–270.
- Schlumberger, H. G., and B. Lucke. 1948. Tumors of fishes, amphibians, and reptiles. *Cancer Research* 8:657–753.
- Smith, G. M., and C. W. Coates. 1938. Fibro-epithelial growths of the skin in large marine turtles, *Chelonia mydas* (Linnaeus). *Zoologica (New York)* 23:93–98.
- Smith, G. M., and C. W. Coates. 1939. The occurrence of trematode ova, *Hapalotrema constrictum* (Leared), in fibroepithelial tumours of the marine turtle, *Chelonia mydas* (Linnaeus). *Zoologica (New York)* 24:379–380.
- Sundberg, J. P. 1991. Etiologies of papillomas, fibropapillomas, fibromas, and squamous cell carcinomas in animals. Pages 75–76 in Balazs and Pooley (1991).
- White, D. O., and F. Fenner. 1986. *Medical virology*, 3rd edition. Academic Press, Orlando, Florida.
- Williams, E. H., Jr., and L. Bunkley-Williams. 1990. The worldwide coral reef bleaching cycle and related sources of coral mortality. *Atoll Research Bulletin* 335:1–71.
- Williams, E. H., Jr., L. Bunkley-Williams, and E. M. Bureson. 1994. Some new records of marine and freshwater leeches from Caribbean, southeastern U.S.A., eastern Pacific, and Okinawan animals. *Journal of the Helminthological Society of Washington* 61:129–134.