

See discussions, stats, and author profiles for this publication at: <https://www.researchgate.net/publication/240765640>

# Angiodictyum mooreae n. sp. (Digenea: Microscaphidiidae) and Other Digeneans from an Atlantic Hawksbill Turtle *Eretmochelys imbricata imbricata* from Puerto Rico

Article in *Journal of Aquatic Animal Health* · March 1995

DOI: 10.1577/1548-8667(1995)007<0038:AMNSDM>2.3.CO;2

CITATIONS

12

READS

40

3 authors, including:



**Ernest H. Williams, Jr**

University of Puerto Rico at Arecibo

158 PUBLICATIONS 3,116 CITATIONS

[SEE PROFILE](#)



**Lucy Bunkley Williams**

University of Puerto Rico at Mayagüez

111 PUBLICATIONS 2,220 CITATIONS

[SEE PROFILE](#)

Some of the authors of this publication are also working on these related projects:



Life cycle and life history strategies of parasitic Crustacea [View project](#)

***Angiodictyum mooreae* n. sp. (Digenea: Microscophiidae)  
and Other Digeneans from an Atlantic Hawksbill Turtle  
*Eretmochelys imbricata imbricata* from Puerto Rico**

WILLIAM G. DYER

Department of Zoology, Southern Illinois University, Carbondale, Illinois 62901-6501, USA

ERNEST H. WILLIAMS, JR., AND LUCY BUNKLEY-WILLIAMS

Caribbean Aquatic Animal Health Project, Department of Marine Sciences  
University of Puerto Rico, Post Office Box 908, Lajas, Puerto Rico 00667-0908, USA

**Abstract.**—A specimen of the endangered hawksbill sea turtle, illegally speared and killed near La Parguera, Puerto Rico, was examined for helminths during postmortem examination. Four microscophiids, *Angiodictyum mooreae* n. sp., *A. parallelum*, *A. anteroporum*, and *Octangium sagitta*; one spirorchiid, *Learedius learedi*; and one pronocephalid, *Cricocephalus megastomus*, were detected. *Angiodictyum mooreae* may be distinguished from all known species of *Angiodictyum* in possessing large prominent marginal bodies. It is most similar to *A. parallelum* but differs in having a genital pore located immediately posterior to the oral sucker and in having 25–26 marginal bodies on each side. The findings of *A. parallelum* and *A. anteroporum* in an Atlantic hawksbill turtle constitute new host records and, for the latter parasite, a new geographic locality record.

For centuries the hawksbill sea turtle has been prized for its meat and carapace scutes called “tortoise shell.” Because of overexploitation and habitat destruction, populations appear to be declining over much of the species’ range. Thus, it is considered an endangered species by the scientific and conservation community (Witzell 1983). As a consequence of worthy national and international protection regulations that forbid killing hawksbill turtles, information on the diversification and distribution of hawksbill parasites over the species’ range is not available.

A single Atlantic hawksbill turtle was illegally speared and killed near La Parguera, Puerto Rico, on 4 June 1993. The individual responsible for the death of this turtle was incarcerated and the specimen was awarded to the Caribbean Stranding Network. Helminths were collected during postmortem examination with the hope of gaining new information about the parasitic fauna. Four microscophiids and one pronocephalid were found in the digestive tract and one spirorchiid in the cardiac cavity. All other tissues were negative for helminths.

#### Methods

The digestive tract, lungs, circulatory system, liver, and urinary bladder were examined for helminths shortly after the turtle’s death. Specimens were collected alive and fixed in hot AFA, stained in Harris’ hematoxylin, dehydrated, cleared in beechwood creosote, and mounted in Canada bal-

sam. Voucher specimens were deposited in the U.S. National Museum (USNM) Helminthological Collection as noted. For comparative purposes specimens were borrowed from the USNM in Beltsville, Maryland, labeled as follows: paratype *Learedius learedi* Price, 1934 (USNM 32567); *Learedius orientalis* Mehra, 1939 (USNM 73322); and *Cricocephalus megastomus* Looss, 1902 (USNM 73329).

#### Characteristics of *Angiodictyum mooreae* n. sp.

**Description** (based on three adult worms from one Atlantic hawksbill turtle; Figure 1): Microscophiidae; Microscophiinae, *Angiodictyum* Looss, 1902. Elongate monostome with body tapering anteriorly, rounded posteriorly, 2.48–3.20 mm long (mean, 2.90 mm), 550–768 (659)  $\mu\text{m}$  wide at level of anterior testis. Ventral surface spinose with 25–26 large marginal bodies on each side. Oral sucker terminal, 230–450 (340)  $\mu\text{m}$  long, 130–225 (165)  $\mu\text{m}$  wide. Esophagus narrow, 470–582 (575)  $\mu\text{m}$  long with broad muscular swelling—130–190 (178)  $\mu\text{m}$  long by 70–110 (100)  $\mu\text{m}$  wide—at the posterior end; ceca saccular at posterior ends, terminating blindly 250–450 (320)  $\mu\text{m}$  from posterior extremity. Testes round with smooth margins, tandem, in middle third of body: anterior testis 210–380 (260)  $\mu\text{m}$  long, 290–380 (326)  $\mu\text{m}$  wide; posterior testis 230–380 (283)  $\mu\text{m}$  long, 230–385 (300)  $\mu\text{m}$  wide. Seminal vesicle saccular, between anterior testis and cecal bifurcation, extending anteriorly as tubular duct along esophagus, forming

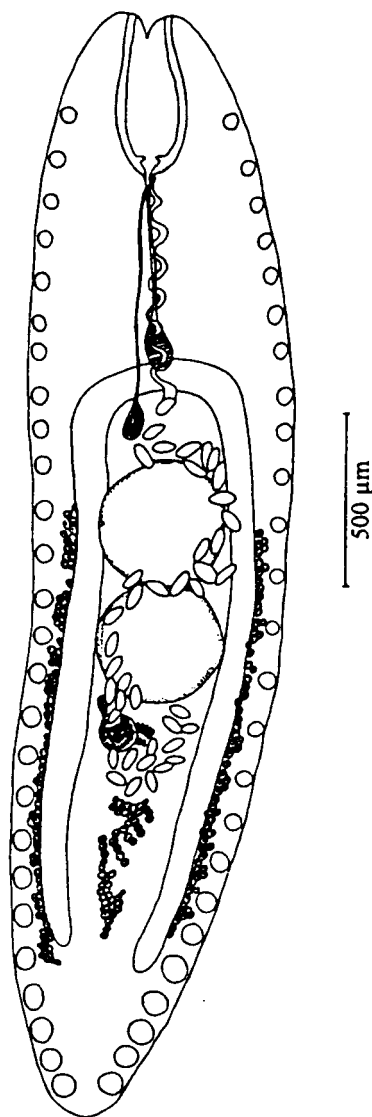


FIGURE 1.—Ventral view of holotype of *Angiodictyum mooreae* n. sp.

pars prostatica and terminal ejaculatory duct. Genital sinus terminating as genital pore immediately posterior to oral sucker. Ovary post-testicular, spherical with smooth margins, 80–120 (87)  $\mu\text{m}$  long, 90–125 (97)  $\mu\text{m}$  wide. Seminal receptacle pre-ovarian; Mehlis' gland medial to ovary; Laurer's canal not observed. Vitellaria follicular, with extracecal and intercecal groups; extracecal group extending from midlevel of anterior testis to cecal ends, intercecal group extending from posterior limit of uterus and terminating 480–500 (490)  $\mu\text{m}$  from posterior end of body. Uterus passing around posterior end of ovary, then ascending intercecally

between testes, overlapping seminal vesicle, continuing ventral to esophagus, terminating as short metraterm before entering genital sinus. Eggs in uterus 66–77 (67)  $\mu\text{m}$  long by 35–43 (37)  $\mu\text{m}$  wide ( $N = 15$ ).

*Host*: *Eretmochelys imbricata imbricata* (Linnaeus) (Testudinata: Cheloniidae).

*Locality*: La Parguera, Puerto Rico, 17°58'30"N, 67°02'45"W.

*Site of infestation*: Large intestine.

*Etymology*: Named for Debra P. Moore in recognition of her contribution to the study of marine turtles.

*Type material*: U.S. National Museum Helminthological Collection. Holotype, number 83406; paratypes, number 83407.

*Remarks*: Marginal bodies along the ventrolateral part of the body are either very small or absent in members of the genus *Angiodictyum* Looss, 1902. *Angiodictyum parallelum* (Looss, 1901) Looss, 1902, has 13–16 marginal bodies on each side. In her description of *A. posterovitellatum* and *A. anteroporum*, Chattopadhyaya (1972) did not indicate the number of minute marginal bodies present. Blair (1986) did not find marginal bodies on specimens of *A. posterovitellatum* he examined from the green turtle *Chelonia mydas* in Queensland, Australia. Blair (1986) described *A. longum* and *A. glossoides* as having 23–31 and 8–9 marginal bodies on each side, respectively.

*Angiodictyum mooreae* sp. n. may be readily distinguished from other members of this genus in that it possesses large, prominent marginal bodies along the ventrolateral part of the body. Our form appears closest to *A. parallelum* but differs in having the genital pore located immediately posterior to the oral sucker, rather than well apart from it, and in having 25–26 large marginal bodies on each side, rather than 13–16 small marginal bodies on each side.

Five species of *Angiodictyum* are known from marine turtles: one from the hawksbill turtle, three from the green turtle, and one from both species. Looss (1901) erected the genus *Microscaphidium* to accommodate *Microscaphidium parallelum* taken from the intestine of a green turtle in Alexandria, Egypt. The following year, Looss (1902) erected a new genus, *Angiodictyum*, to accommodate *Microscaphidium parallelum*, which was transferred to *Angiodictyum* as the type species, becoming *A. parallelum* (Looss, 1901) Looss, 1902. It was later reported from the large intestine of a green turtle in Florida by Nigrelli (1941). Chattopadhyaya (1972) described *A. anteroporum* from the large intestine of a green turtle from Pam-

ban, south India, and *A. posterovitellatum* from the lower part of the intestine of a hawksbill turtle from Mandapam, south India. *Angiodictyum posterovitellatum* has also been reported from the large intestine of a green turtle from Queensland, Australia. Blair (1986) described *A. longum* from the pseudocaecum of a green turtle from Queensland and from the large intestines of green turtles from the Straits of Malacca, Malaysia, and Sri Lanka. Blair (1986) also described *A. glossoides* from the intestine of a hawksbill turtle from Río Cañaveral on the Caribbean coast of Panama.

The finding of *A. parallelum* in an Atlantic hawksbill turtle constitutes a new host record, and the finding of *A. anteroporum* in this turtle from Puerto Rico constitutes new host and geographic locality records.

### Microscaphidiidae

#### *Angiodictyum parallelum* (Looss, 1901)

Looss, 1902

One mature and nine immature angiodictyids were detected in the large intestine. Measurements and morphological features of the mature specimen are in close agreement with those for *A. parallelum*. Measurements of the immature specimens were not recorded. The number of marginal bodies in immature specimens ranged from 13 to 16, similar to that reported for this species by Blair (1986).

*Dimensions* ( $N = 1$ ): Body 6.5 by 1.1 mm, marginal bodies 16 on each side, oral sucker 282 by 256  $\mu\text{m}$ , esophagus 154 by 78  $\mu\text{m}$ , esophageal bulb 231  $\mu\text{m}$  long, anterior testis by 332 by 384  $\mu\text{m}$ , posterior testis 384 by 384  $\mu\text{m}$ , ovary 153 by 179  $\mu\text{m}$ , eggs 112 by 63  $\mu\text{m}$ . The mature and five of the immature specimens have been deposited in the USNM Helminthological Collection as number 83380.

#### *Angiodictyum anteroporum*

Chattopadhyaya, 1972

Three mature monostomes from the large intestine, although slightly smaller, agree with the morphological description of *A. anteroporum* as given by Chattopadhyaya (1972).

*Dimensions* ( $N = 3$ ): Body 2.5–3.2 (2.7) by 0.5–0.8 (0.7) mm, oral sucker 77–143 (120) by 66–74 (67)  $\mu\text{m}$ , esophagus 143–620 (409)  $\mu\text{m}$ , esophageal bulb 110–115 (112) by 33–100 (59)  $\mu\text{m}$ , anterior testis 110–220 (150) by 190–400 (280)  $\mu\text{m}$ , posterior testis 110–180 (133) by 210–410 (316)  $\mu\text{m}$ , ovary 70–100 (87) by 110–200 (150)  $\mu\text{m}$ , eggs 66–77 (74) by 31–34 (33)  $\mu\text{m}$ . The three specimens have been deposited in the USNM Helminthological Collection as number 83381.

#### *Octangium sagitta* (Looss, 1899) Looss, 1902

Seven mature specimens of a microscaphidiid from the large intestine agree quite well with specimens of *O. sagitta* described by Looss (1902) and reexamined later by Blair (1987).

*Dimensions* ( $N = 7$ ): Body 2.4–5.6 (4.3) by 0.9–1.4 (1.2) mm, oral sucker 200–270 (244) by 170–270 (235)  $\mu\text{m}$ , esophagus 400–1,050 (770)  $\mu\text{m}$ , esophageal bulb 290–400 (324) by 190–300 (272)  $\mu\text{m}$ , distance from fork of ceca to anterior testis 350–700 (430)  $\mu\text{m}$ , anterior testis 250–540 (418) by 120–300 (230)  $\mu\text{m}$ , posterior testis 300–550 (458) by 150–350 (266)  $\mu\text{m}$ , ovary 140–300 (189) by 60–193 (190)  $\mu\text{m}$ , eggs 61–77 (67) by 33–36 (35)  $\mu\text{m}$ . The seven specimens have been deposited in the USNM Helminthological Collection as number 83383.

*Remarks*: Blair (1987) conducted a comparative study of all species reported in this genus and concluded that *O. sagitta* and *O. hypalum* Blair, 1987, were the only valid species. These two species may be differentiated by *O. hypalum* having three pairs of primary ducts in the excretory plexus, the more anterior placement of the testes, the shorter lateral vitelline field, and a relatively larger esophageal bulb. He considered *O. hasta* Looss, 1902, and *O. takanoi* Kobayashi, 1921, synonyms of *O. sagitta*. *Octangium sagitta* has been reported in green turtles from the Mediterranean coast of Egypt and from Australia, India, Singapore, Taiwan, and Puerto Rico. It has also been reported in hawksbill turtles from India and Puerto Rico. *Octangium hypalum*, of which *O. takanoi* Kobayashi sensu Tandon and Gupta (1981) is considered a synonym according to Blair (1987), has been reported from the pseudocecum of a green turtle from Queensland, Australia.

### Pronocephalidae

#### *Cricocephalus megastomus* Looss, 1902

Three mature and two immature specimens of pronocephalids found in the stomach were identified as *Cricocephalus megastomus*. This species was described by Looss (1902) from specimens found in green turtles from Egypt. Our specimens are slightly smaller than those of Looss.

*Dimensions* ( $N = 3$ ): Body 2.2–2.8 (2.4) by 0.9–1.1 (0.9) mm, oral sucker 500–700 (593) by 590–780 (623)  $\mu\text{m}$ , esophagus 270–340 (316)  $\mu\text{m}$ , right testis 190–200 (195) by 150–190 (163)  $\mu\text{m}$ , left testis 198–200 (199) by 148–152 (150)  $\mu\text{m}$ , ovary 120–170 (146) by 140–190 (163)  $\mu\text{m}$ , eggs 31–33 (32) by 13–14 (13)  $\mu\text{m}$ . The three mature speci-

mens have been deposited in the USNM Helminthological Collection as number 83382.

**Remarks:** Three species of *Cricocephalus* Looss, 1899, have been found in hawksbill turtles, namely *C. albus* (Kuhl and van Hasselt, 1822) Looss, 1899, in Australia, *C. americanus* Pérez Viguera, 1955, in Cuba, and *C. megastomus* from the West Indies. The latter record was from Cabo Rogo, Puerto Rico, by Fischthal and Acholonu (1976). The present report constitutes the second report from this host in Puerto Rico.

### Spirorchiidae

#### *Learedius learedi* Price, 1934

A single damaged specimen of a spirorchiid identified as *Learedius learedi* was detected in the heart. The genus *Learedius* was proposed by Price (1934) for a single specimen of *L. learedi* detected in the circulatory system of a green turtle that died in the National Zoological Park, Washington, D.C. A more detailed account of this species based on 45 specimens taken from a green turtle in Panama was given by Caballero et al. (1955). Mehra (1939) erected *Learedius orientalis* on the basis of 24 spirorchiids from a green turtle taken in the Arabian Sea. After examination of the holotype of *L. learedi*, we concur with Fischthal and Acholonu (1976) that the only difference between these two species appears to be the relationship of the testes to one another. The testes of *L. learedi* are rounded and somewhat separated from one another, whereas the testes of *L. orientalis* are crowded and abut one another, resulting in flattened margins. Our specimen is designated as *L. learedi* because of the nature of the testes. It is possible, as pointed out by Fischthal and Acholonu (1976), that *L. orientalis* may be a synonym of *L. learedi*. Rand and Wiles (1985) found that eggs of *L. learedi* evoked a granulomatous host reaction with multiple foci in all tissues examined from several moribund green turtles taken from inshore Bermuda waters after storms. We did not detect eggs of *L. learedi* in either the blood or other tissues examined. This species has been reported previously from green turtles in Puerto Rico (Dyer et al. 1991).

### References

- Blair, D. 1986. A revision of the subfamily Microscaphidiinae (Platyhelminthes: Digenea: Microscaphidiidae) parasitic in marine turtles (Reptilia: Chelonia). Australian Journal of Zoology 34:241-277.
- Blair, D. 1987. A revision of the subfamily Octangiinae (Platyhelminthes: Digenea: Microscaphidiidae) parasites in marine turtles (Reptilia: Chelonia). Australian Journal of Zoology 35:75-92.
- Caballero y C., E., M. C. Zerecero y D., and R. G. Crocott. 1955. Helminths de la República de Panamá. XV. Trematodos de *Chelone mydas* (L.) tortuga marina comestible del Océano Pacífico del Norte, 2a parte. Anales del Instituto de Biología Universidad Nacional Autónoma de México 26:149-191.
- Chattopadhyaya, D. R. 1972. Studies on the trematode parasites of reptiles found in India. Contribution to our knowledge of the family Angiodictyidae Looss, 1901. Rivista di Parassitologia 33:1-16.
- Dyer, W. G., E. H. Williams, Jr., and L. Bunkley-Williams. 1991. Some digeneans (Trematoda) of the green turtle, *Chelonia mydas* (Testudines: Cheloniidae) from Puerto Rico. Journal of the Helminthological Society of Washington 58:176-180.
- Fischthal, J. H., and A. D. Acholonu. 1976. Some digenetic trematodes from the Atlantic hawksbill turtle, *Eretmochelys imbricata imbricata* (L.) from Puerto Rico. Proceedings of the Helminthological Society of Washington 43:174-185.
- Looss, A. 1901. Über Trematoden aus Seeschildkröten der ägyptischen Küsten (Notizen zur Helminthologie Egyptens IV). Zentralblatt für Bakteriologie, Parasitenkunde und Infektionskrankheiten, Erste Abteilung Originale 30:555-569, 618-625.
- Looss, A. 1902. Über neue und bekannte Trematoden aus Seeschildkröten, nebst Erörterungen zur Systematik und Nomenclatur. Zoologische Jahrbücher, Abteilung für Systematik. Oekologie und Geographie der Tiere 16:411-894.
- Mehra, H. R. 1939. New blood flukes of the family Spirorchiidae Stunkard (Trematoda) from the marine turtle *Chelone mydas* of the Arabian Sea with observations on the synonymy of certain genera and classification of the family. Proceedings of the National Academy of Sciences, India 9:155-167.
- Nigrelli, R. F. 1941. Parasites of the green turtle, *Chelonia mydas* (L.), with special reference to the rediscovery of trematodes described by Looss from this host species. Journal of Parasitology 27(Supplement):15-16.
- Price, E. W. 1934. New genera and species of blood flukes from a marine turtle, with a key to the genera of the family Spirorchiidae. Journal of the Washington Academy of Sciences 24:132-141.
- Rand, T. G., and M. Wiles. 1985. Histopathology of infections by *Learedius learedi* Price, 1934 and *Neospirorchis schistosomatoides* Price, 1934 (Digenea: Spirorchiidae) in wild green turtles, *Chelonia mydas* L., from Bermuda. Journal of Wildlife Diseases 21:461-463.
- Tandon, V., and N. K. Gupta. 1981. On *Deuterobaris intestinalis* Mehrotra, 1973 and *Octangium takonoi* Kobayashi, 1921 (Trematoda: Microscaphidiidae) from a marine turtle in India. Proceedings of the Indian Academy of Sciences Section B 90:553-560.
- Witzell, W. N. 1983. Synopsis of biological data on the hawksbill turtle, *Eretmochelys imbricata* (Linnaeus, 1766). FAO (Food and Agriculture Organization of the United Nations) Fisheries Synopsis 137.