

A poorly differentiated pulmonary squamous cell carcinoma in a free-ranging Atlantic bottlenose dolphin (*Tursiops truncatus*)

Ruth Y. Ewing, Antonio A. Mignucci-Giannoni

Abstract. A free-ranging, adult, female offshore bottlenose dolphin (*Tursiops truncatus*) was found freshly dead in 1999 on Ocean Park Beach in San Juan, Puerto Rico. The left-lung and right-lung pleura had multiple white, firm-to-hard nodules with coagulative necrosis. Histologically, the neoplasms were characterized by multiple well-circumscribed, nonencapsulated expansile masses consisting mostly of polygonal cells with fewer circumferential flattened basaloid cells that compressed alveoli, bronchioles, and bronchi. Neoplastic cells stained positive for cytokeratin, with sporadic vimentin staining, and were negative for epithelial membrane antigen, thyroid transcription factor-1, calretinin, and human mesothelial cell antigen. A diagnosis of poorly differentiated pulmonary squamous cell carcinoma with lymph node and renal metastases was made on the basis of histomorphology and immunohistochemical staining. This is the first documentation of pulmonary squamous cell carcinoma in a dolphin.

Reported neoplasms of the respiratory tract in odontocetes include reticuloendotheliosis in a bottlenose dolphin and squamous cell carcinoma in an Amazon porpoise.^{9,15} Few neoplasms have been reported in bottlenose dolphins, including renal adenoma, lymphoma, squamous cell carcinoma, and pancreatic carcinoma.^{1,9,15,16,19} A severely emaciated, free-ranging, adult, female offshore Atlantic bottlenose dolphin (*Tursiops truncatus*) was found freshly dead on July 4, 1999, on Ocean Park Beach in San Juan, Puerto Rico. On the basis of histopathology and immunohistochemistry, a diagnosis of poorly differentiated pulmonary carcinoma with lymph node and renal metastases was made. This report describes the morphologic and immunohistochemical features of the first reported poorly differentiated pulmonary squamous cell carcinoma with renal and lymph node metastases in a stranded bottlenose dolphin.

The dolphin was found dead on Ocean Park Beach in San Juan, Puerto Rico (18°27.9'N, 66°03.1'W). Mitochondrial DNA sequence analysis performed on skin samples indicated that this dolphin was of the offshore

(vs. coastal) *Tursiops* morphotype (P. Rosel, unpublished data). Members of the Caribbean Stranding Network of the Southeastern Marine Mammal Stranding Network conducted the necropsy in accordance with standard protocols. (T. A. Jefferson et al.: 1994, Small cetacean dissection and sampling: a field guide. NOAA-TM-NMFS-SWFSC-198. National Technical Information Service, Springfield, VA.) Multiple organ systems were dissected, sampled, and preserved in 10% neutral buffered formalin. Specimens were processed routinely for histopathology into paraffin blocks, sectioned at 4–5 µm, and stained with hematoxylin and eosin (HE). Sections of tumor were stained for vimentin (VIM, 1:1,500), human mesothelial cell antigen (HBME-1, 1:50), keratin AE1/AE3 (1:200), high molecular weight keratin (1:50), epithelial membrane antigen (EMA, 1:1,500), thyroid transcription factor-1^a (TTF-1, 1:150), keratin CAM5.2^b (1:1,500), and calretinin^c (CALRET, 1:200) by immunohistochemistry. The cytokeratin antibodies were combined at the aforementioned dilutions for use, a standard technique followed in the University of Miami, School of Medicine, Pathology Reference Service, Immunoperoxidase Laboratory, Miami, Florida. A mixture of sera from nonimmune normal mouse, rabbit, and goat was applied in lieu of the primary antiserum for negative antibody controls. Normal thyroid and lung sections from another offshore bottlenose dolphin were stained as positive controls for TTF-1. Normal splenic

From the National Oceanographic and Atmospheric Administration, National Marine Fisheries Service, Southeast Fisheries Science Center, Miami, FL 33149, and the Department of Pathology, Division of Comparative Pathology, University of Miami School of Medicine, Miami, FL 33101 (Ewing), and Red Caribeña de Varamientos—Caribbean Stranding Network & Departamento de Ciencias y Tecnología, Universidad Metropolitana, San Juan, Puerto Rico 00936 (Mignucci-Giannoni).

serosal mesothelium from a bottlenose dolphin was stained as control for CALRET and HBME-1. The CALRET was immunoreactive, whereas the HBME-1 was not. Routine human known positive controls were used for all other immunohistochemical stains (M. Nadji, personal communication).

The dolphin was 273 cm in length from rostrum to tail notch and weighed 149.1 kg. Grossly, the dolphin was severely emaciated with protruding scapulae, ribs, and vertebral transverse processes. The lungs and major bronchi contained frothy white fluid and were diffusely congested. Most of the left lung was diffusely and severely affected with multiple irregular, round-to-oval, white, firm-to-hard areas of approximately 2–3 cm with coagulative necrosis. There were similar smaller discrete nodules along the visceral pleura of the right lung. All thoracic lymph nodes were enlarged and mottled white and maroon on cut section.

Histologically, the pulmonary parenchyma contained multiple well-circumscribed, nonencapsulated expansile masses, which compressed and/or infiltrated alveoli, bronchioles, and bronchi. The neoplastic cells had a squamous morphology consisting of mostly polygonal cells, with a mantle of flattened basaloid cells (Fig. 1A). The polygonal cells had moderate eosinophilic cytoplasm, distinct cell borders, round-to-elongate hyperchromatic or vesicular nuclei, and occasional single prominent nucleoli (Fig. 1B). There was moderate variability in the sizes of cells and nuclei; mitoses were infrequent at 1–2 per high-power field. The cells were arranged in variably sized nests with frequent central necrosis, neutrophilic inflammatory cell infiltration, and a mild, thin, dense, fibrous stroma. The pleural lymphatic channels and blood vessels contained individual or clustered neoplastic cells.

The normal offshore bottlenose dolphin thyroid and lung sections had positive follicular and respiratory epithelial cell nuclear staining for TTF-1. Normal dolphin splenic serosal mesothelium stained positive for CALRET but was negative for HBME-1. The cytokeratin markers were diffusely and strongly positive in all neoplastic cells with peripheral cytoplasmic staining (Fig. 1C). Neoplastic cells were nonimmunoreactive for EMA, TTF-1, HBME-1, and CALRET and were sporadically positive for VIM.

The normal architecture of a thoracic lymph node was mostly effaced by similar neoplastic cells admixed with moderate, multifocal, neutrophilic inflammatory cell infiltration and necrotic cellular debris. A reniculus had a glomerular metastatic focus, which replaced the glomerular tuft and distended the Bowman's capsule. In addition, the renal metastatic focus was similarly immunoreactive for all cytokeratin markers used. Occasional keratin protein-reactive neoplastic cells were present within renal interlobular artery lumina.

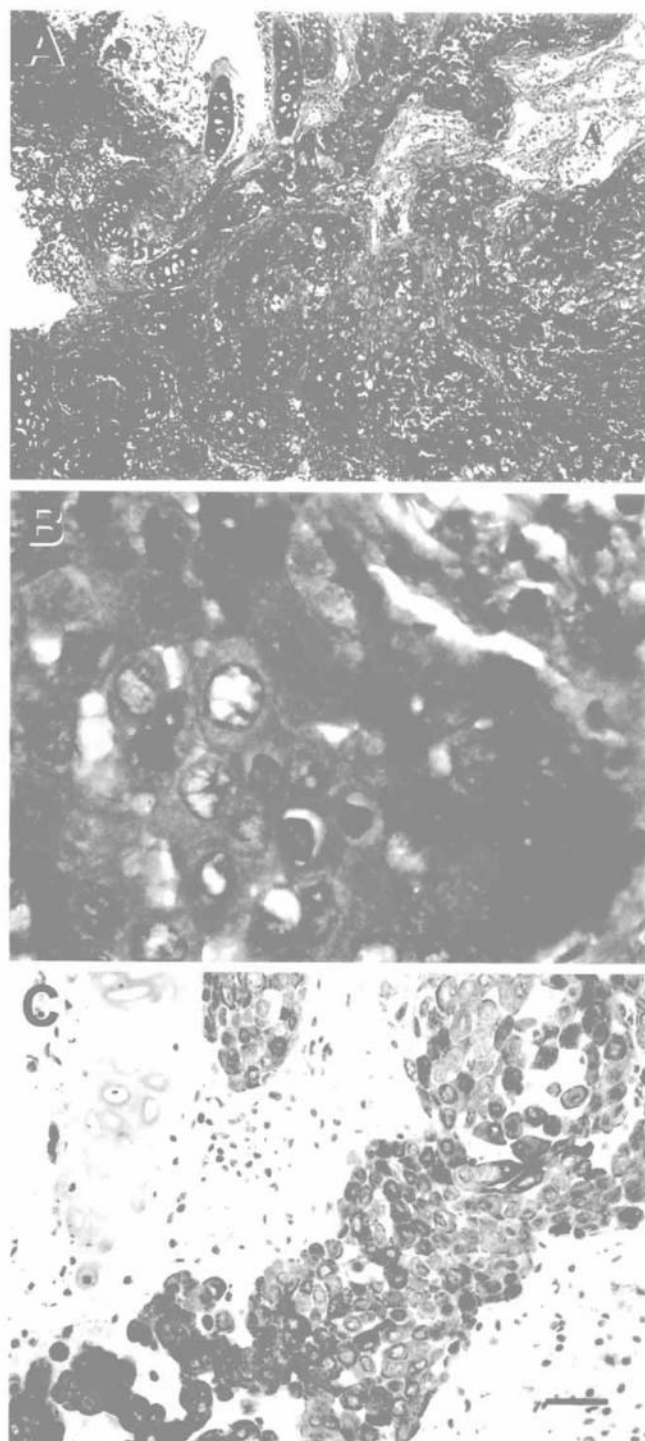


Figure 1. A, Lung; bottlenose dolphin. Poorly differentiated carcinoma. Variably sized nests of polyhedral cells distorting bronchioles (Br) and alveoli (A) with frequent central necrosis and a thin, dense, fibrous stroma (arrows). HE. Bar = 200 μ m. B, Lung; bottlenose dolphin. Poorly differentiated carcinoma. Neoplastic cells with moderate eosinophilic cytoplasm, round-to-elongate hyperchromatic or vesicular nuclei, distinct cell borders, anisokaryosis, anisocytosis, and occasional binucleation. HE. Bar = 10 μ m. C, Lung; bottlenose dolphin. Poorly differentiated carcinoma. Neoplastic cells were diffusely and strongly immunoreactive for the combined cytokeratin antibodies with occasional marked peripheral staining. Avidin-biotin-diaminobenzidine-peroxidase complex method with hematoxylin counterstain. Bar = 50 μ m.

The renal tubular epithelial cells had weak diffuse EMA cytoplasmic staining, whereas the metastatic focus was negative for EMA.

Despite the lack of classical characteristic features of a squamous cell carcinoma, the neoplasm morphology, degree of cellular anaplasia, and immunostaining characteristics were consistent with a diagnosis of poorly differentiated squamous cell carcinoma. Differential diagnoses included a primary bronchogenic carcinoma and mesothelioma. A metastatic epithelial cell tumor was considered to be unlikely because a larger primary neoplasm was not observed elsewhere in the carcass; however, an occult neoplasm could not be ruled out.

Epithelial membrane antigen and cytokeratin proteins are markers for epithelial differentiation; however, EMA is neither as sensitive nor as specific as keratin.¹⁷ Keratin proteins have strong immunoreactivity for squamous cell carcinoma and mesothelioma. In human surgical pathology, EMA is considered a marker for epithelial differentiation and is immunoreactive for adenocarcinomas of various primary locations; however, certain mesenchymal and lymphoreticular neoplasms also show immunoreactivity.¹⁷ There are also discrepancies regarding EMA reactivity in mesothelioma and squamous cell carcinoma between investigators reporting both positive and negative results.¹⁷

Thyroid transcription factor-1 is a nuclear transcription protein and a tissue-specific factor that is expressed in human thyroid follicular cells, bronchial and alveolar epithelium, and the diencephalon.⁷ Immunoreactivity to TTF-1 has been used to distinguish positive primary pulmonary adenocarcinoma from metastatic adenocarcinoma and mesothelioma, which tend to be nonimmunoreactive (M. Nadji, personal communication). In humans, pulmonary squamous cell carcinomas are nonimmunoreactive for TTF-1 (M. Nadji, personal communication). The normal dolphin thyroid and lung sections had positive epithelial nuclear staining for TTF-1, supporting its use as a tissue-specific marker in dolphins. Nonspecific staining of mesenchymal cells, by TTF-1, in sections from the control and case specimens was not observed nor was there false-positive immunoreactivity for renal epithelial cells in the case specimen. The neoplastic cells in the lung, lymph node, and retractor were nonimmunoreactive for TTF-1 and EMA but had strong keratin protein immunodetection.

Vimentin, HBME-1, and CALRET antibody stains were applied to differentiate carcinoma from malignant mesothelioma. Neoplastic cells were nonimmunoreactive for HBME-1 and CALRET and showed sporadic positive staining for VIM. Although there is controversy regarding definitive staining features of human mesotheliomas, most studies indicate that CALRET and HBME-1 are highly specific and sen-

sitive markers for mesotheliomas.^{8,18} Normal mesothelial cells from a dolphin spleen stained positive for CALRET, confirming the use of this antibody in this species. However, HBME-1 antibody failed to stain normal dolphin splenic mesothelial cells; therefore, interpretation of this stain is limited. Vimentin has also been shown to positively stain human mesothelioma tumor cells; however, the frequency of positive staining is variable.²⁰ In addition, VIM, typically a mesenchymal cell marker, has been shown to stain other carcinomas and may reflect epithelial-mesenchymal transition events.⁵ These findings lend support to ruling out malignant mesothelioma as a differential diagnosis for this neoplasm.

Primary pulmonary squamous cell carcinoma is relatively uncommon in nonhuman mammalian species. In humans, there is a positive correlation between lung cancer and tobacco smoking, chronic industrial hazard exposure, air pollution, molecular genetic alterations, and scar tissue.¹⁴ In humans, scar tissue is an antecedent to bronchogenic carcinoma and squamous cell carcinoma development and is also a desmoplastic response to the neoplasm.¹⁴ Exuberant or aberrant forms of inflammatory, reparative, and regenerative processes may serve as predisposing factors for oncogenesis.²

Bronchial and bronchiolar mucosal mineralization, pulmonary granulomas, and verminous bronchopneumonia are not uncommon in both free-ranging offshore and coastal bottlenose dolphins (Ewing et al., unpublished data). Various genera of lung nematodes have been described in both coastal and pelagic small odontocetes.³ There is reported circumstantial evidence of prenatal *Halocercus lagenorhynchi* infection with transplacental transmission in the Atlantic bottlenose dolphin.⁴ *Halocercus* sp. have prominent cuticular spines that stimulate mucus production, marked acute inflammation, epithelial desquamation, hemorrhage, and Type II pneumocyte hyperplasia. These changes progress to pyogranulomas, histiocytic granulomas, reparative fibrosis, fibrous encapsulation, and mineralization that characterize the chronic phase of inflammation.¹¹ Bronchiolar squamous metaplasia has not commonly been described as a characteristic of dolphin pulmonary nematodiasis; however, this was observed in an unrelated case of another offshore bottlenose dolphin with pulmonary halocerciasis (Ewing, unpublished data). In this species, persistent pulmonary nematodiasis may induce neoplastic transformation in metaplastic epithelium. Parasite-induced oncogenesis has been observed historically in rats, dogs, and humans associated with *Cysticercus fasciolaris*, *Spirocerca lupi*, and *Schistosoma haematobium*, respectively.¹³

Human papillomavirus-induced juvenile laryngotracheal and pulmonary papillomatosis with malignant

transformation can cause pulmonary squamous cell carcinoma.¹⁰ Papillomavirus-induced malignant transformation is recognized in cattle and is suspected in goats and rabbits.¹² Papillomavirus has not been described in Atlantic offshore bottlenose dolphins; however, papillomavirus-like or papillomatosis infections have been reported in killer whales, harbor porpoise, Atlantic white-sided dolphins, narwhal, and beluga whales.^{6,9,15}

The offshore Atlantic bottlenose dolphin is a pelagic species that uses a different habitat and has a social structure different from that of coastal bottlenose dolphins. Exposure to most anthropogenic toxins/carcinogens is presumably less in pelagic species; however, certain airborne contaminants can have far-reaching effects and are known to persist in the environment. The cause of the neoplasm in this case is unknown. However, persistent pulmonary nematodiasis may have induced neoplastic transformation in metaplastic epithelium because of chronic irritation, possibly in concert with a viral cohort or secondary to an inadequate immune response. Interestingly, pulmonary nematodiasis was not observed at gross necropsy. Possible future investigation would include a search for a viral, toxic, or carcinogenic etiology, molecular genetic alteration, and immune status. This case represents the first report and characterization of pulmonary squamous cell carcinoma with metastasis in an offshore Atlantic bottlenose dolphin.

Acknowledgements. We would like to thank the volunteer members of the Caribbean Stranding Network who assisted in the salvage and necropsy, especially M. A. Cardona, E. Rivera, A. Deleo, and B. Carrasquillo. We also thank Drs. B. Homer, R. Manduca, and J. Zaias for editorial comments, Dr. M. Nadjj for immunohistochemical expertise, Dr. P. Rosel for genetic analysis, and Dr. M. Lara for technical assistance. These samples were collected in accordance with the authority granted by the joint National Marine Fisheries Service (NMFS) and United States Fish and Wildlife Service (USFWS) Permit 932-1489-01/PRT009526 to the Marine Mammal Health and Stranding Response Program. The findings and opinions contained in this report are those of the authors and should not be construed as an official Department of Commerce, National Oceanographic and Atmospheric Administration (NOAA), NMFS position unless designated by other documentation.

Sources and manufacturers

- a. Dako, Carpinteria, CA.
- b. Becton Dickinson, Mountain View, CA.
- c. Zymed, South San Francisco, CA.

References

1. Bossart GD, Ewing R, Herron AJ, et al.: 1997, Immunoblastic malignant lymphoma in dolphins: histologic, ultrastructural, and immunohistochemical features. *J Vet Diagn Invest* 9:454–458.
2. Cotran RS, Kumar V, Collins T: 1999, Neoplasia. In: Robbins pathologic basis of disease, eds. Cotran RS, Kumar V, Collins T, 6th ed., pp. 260–325. WB Saunders, Philadelphia, PA.
3. Dailey MD, Brownell RL: 1972, A checklist of marine mammal parasites. In: Mammals of the sea: biology and medicine, ed. Ridgway S, pp. 528–598. Thomas, Springfield, IL.
4. Dailey MD, Walsh M, Odell D, Campbell T: 1991, Evidence of prenatal infection in the bottlenose dolphin (*Tursiops truncatus*) with the lungworm *Halocercus lagenorhynchi* (Nematoda: Pseudaliidae). *J Wildl Dis* 27:164–165.
5. Dandachi N, Hauser-Kronberger C, More E, et al.: 2001, Co-expression of tenascin-C and vimentin in human breast cancer cells indicates phenotypic transdifferentiation during tumour progression: correlation with histopathological parameters, hormone receptors, and oncoproteins. *J Pathol* 193:181–189.
6. DeGuise S, Lagacé A, Béland P: 1994, Gastric papillomas in eight St. Lawrence beluga whales. *J Vet Diagn Invest* 6:385–388.
7. Folpe AL, Gown AM, Lamps LW, et al.: 1999, Thyroid transcription factor-1: immunohistochemical evaluation in pulmonary neuroendocrine tumors. *Mod Pathol* 12:5–8.
8. Garcia-Prats MD, Ballestin C, Sotelo T, et al.: 1998, A comparative evaluation of immunohistochemical markers for the differential diagnosis of malignant pleural tumours. *Histopathology* 32:462–472.
9. Geraci JR, Palmer NC, St. Aubin DJ: 1987, Tumors in cetaceans: analysis and new findings. *Can J Fish Aquat Sci* 44:1289–1300.
10. Guillou L, Sahli R, Chaubert P, et al.: 1991, Squamous cell carcinoma of the lung in a nonsmoking, nonirradiated patient with juvenile laryngotracheal papillomatosis. Evidence of human papillomavirus-11 DNA in both carcinoma and papillomas. *Am J Surg Pathol* 15:891–898.
11. Howard EB, Britt JO, Matsumoto G: 1983, Parasitic diseases. In: Pathology of marine mammal diseases, ed. Howard EB, vol. 1, pp. 120–232. CRC Press, Boca Raton, FL.
12. Jones TC, Hunt RD, King NW: 1997, Diseases caused by viruses. In: Veterinary pathology, 6th ed., pp. 197–370. Williams & Wilkins, Baltimore, MD.
13. Jones TC, Hunt RD, King NW: 1997, Diseases caused by parasitic helminths and arthropods. In: Veterinary pathology, 6th ed., pp. 601–680. Williams & Wilkins, Baltimore, MD.
14. Kobzik L: 1999, The lung. In: Robbins pathologic basis of disease, eds. Cotran RS, Kumar V, Collins T, 6th ed., pp. 741–753. WB Saunders, Philadelphia, PA.
15. Landy RB: 1980, A review of neoplasia in marine mammals. In: The comparative pathology of zoo animals, eds. Montali RJ, Migaki G, pp. 579–583. Smithsonian Institution Press, Washington, DC.
16. Migaki G, Woodard JC, Goldston RT: 1978, Renal adenoma in an Atlantic bottlenose dolphin (*Tursiops truncatus*). *Am J Vet Res* 39:1920–1921.
17. Nadjj M, Morales AR: 1986, Immunoperoxidase techniques: a practical approach to tumor diagnosis. American Society of Clinical Pathologist Press, Chicago, IL.
18. Ordonez NG: 1999, The immunohistochemical diagnosis of epithelial mesothelioma. *Hum Pathol* 30(3):313–323.
19. Renner MS, Ewing R, Bossart GD, Harris D: 1999, Sublingual squamous cell carcinoma in an Atlantic bottlenose dolphin (*Tursiops truncatus*): a case report. *J Zoo Wildl Med* 30:573–576.
20. Roberts F, Path MRC, Harper C, et al.: 2001, Immunohistochemical analysis still has a limited role in the diagnosis of malignant mesothelioma. *Am J Clin Pathol* 116:253–262.